



Periocular keratoacanthoma: can we always rely on the clinical diagnosis?

I Leibovitch, S C Huilgol, C L James, J D Hsuan, G Davis and D Selva

Br. J. Ophthalmol. 2005;89;1201-1204
doi:10.1136/bjo.2005.072470

Updated information and services can be found at:
<http://bjournal.bmj.com/cgi/content/full/89/9/1201>

These include:

References

This article cites 18 articles, 2 of which can be accessed free at:
<http://bjournal.bmj.com/cgi/content/full/89/9/1201#BIBL>

Rapid responses

You can respond to this article at:
<http://bjournal.bmj.com/cgi/eletter-submit/89/9/1201>

Email alerting service

Receive free email alerts when new articles cite this article - sign up in the box at the top right corner of the article

Notes

To order reprints of this article go to:
<http://journals.bmj.com/cgi/reprintform>

To subscribe to *British Journal of Ophthalmology* go to:
<http://journals.bmj.com/subscriptions/>

EXTENDED REPORT

Periocular keratoacanthoma: can we always rely on the clinical diagnosis?

I Leibovitch, S C Huilgol, C L James, J D Hsuan, G Davis, D Selva

Br J Ophthalmol 2005;89:1201–1204. doi: 10.1136/bjo.2005.072470

See end of article for authors' affiliations

Correspondence to: Mr J Hsuan, Department of Ophthalmology, Walton Hospital, Rice Lane, Liverpool L9 1AE, UK; leiboigal5@yahoo.com.au

Accepted for publication 28 April 2005

Aim: To present a series of patients with a clinical diagnosis of periocular keratoacanthoma and assess the incidence of histologically proven invasive squamous cell carcinoma (SCC).**Methods:** This retrospective case series included all patients with periocular tumours seen in the authors' unit between 1996 and 2004, and who were initially diagnosed with keratoacanthoma based on the clinical presentation.**Results:** Twelve patients (eight males, four females) were clinically diagnosed with keratoacanthoma. The final histological diagnosis revealed two cases (16.7%) of invasive SCC, and 10 cases (83.3%) of keratoacanthoma. The lower lid was most commonly involved in cases of keratoacanthoma (50.0%). Six patients (60.0%) underwent Mohs surgery, and four (40.0%) were treated with excision under frozen section control. There were no cases of recurrence during a mean follow up period of 21 (SD 13) months.**Conclusion:** Although the clinical presentation of periocular keratoacanthoma is usually characteristic, a significant percentage of patients will prove to have invasive SCC. Complete excision with margin control offers a definitive diagnosis, as well as tissue conservation and a low recurrence rate.

Keratoacanthoma is a unique entity in skin cancer, characterised by a very rapid growth phase, followed by gradual involution.^{1–5} Some authors see it as a distinctive tumour,^{1–3} whereas others define it as a subtype of squamous cell carcinoma (SCC), and treat it accordingly.^{4,5}

The tumour is most commonly seen on sun exposed and hair bearing areas of elderly patients, mainly on the face, forearms, and hands.^{3,4} Periocular involvement is not common, and there are only a few series on the clinical presentation and treatment of keratoacanthoma in this area.^{6–10}

Although the morphological features of keratoacanthoma are quite distinctive, a definite distinction from invasive SCC can only be made histologically. In this retrospective series we review all cases of periocular tumours diagnosed as keratoacanthoma based on the clinical presentation and discuss the cases eventually diagnosed with invasive SCC.

METHODS

This is a retrospective, non-comparative, interventional case series of all patients with periocular tumours which were diagnosed as keratoacanthoma based on the clinical and morphological features and a preoperative biopsy. All patients were seen at the Oculoplastic Unit at the Royal Adelaide Hospital between 1998 and 2004. The patient database was reviewed and all patients who had a preoperative diagnosis of keratoacanthoma were selected.

The main data recorded were patients' demographics, duration of tumour, tumour site, preoperative tumour size, histological diagnosis and evidence of perineural invasion, number of excision levels, postoperative defect size, recurrence post-treatment, and postoperative complications.

The final diagnosis in all patients was based on the histological analysis of the resected tumours by an experienced dermatopathologist.

RESULTS

There were 12 patients (eight males, four females) who were diagnosed with keratoacanthoma based on the clinical tumour characteristics. An initial incisional biopsy in all

cases showed a squamo-proliferative process, but after complete tumour removal, the final histological diagnosis of keratoacanthoma was confirmed in 10 patients (83.3%) (table 1). The other two patients (16.7%) were diagnosed with an invasive (moderate to well differentiated) SCC (table 2).

The 10 patients with a confirmed diagnosis of keratoacanthoma included six males and four females with a mean (standard deviation) age of 67 (SD 12) years (median 70; range 41–81) (table 1). The mean duration from tumour appearance to clinical diagnosis was 10 (SD 5) weeks (median 8; range 4–20 weeks). The tumour was located in the lower lid in five cases (50%), upper lid in two cases (20%), medial canthus in two cases (20%), and lateral canthus in one case (10%). There was an equal distribution between the right and left sides (50%). Mean tumour size was 12 (SD 6) mm (median 10.5; range 5–20 mm).

Six patients (60%) underwent Mohs surgery, and four (40%) were treated with excision under frozen section control. No cases of perineural or vascular invasion were noted on final histology. The various reconstruction methods used are presented in table 1. There were no cases of complications or recurrence during a mean follow up of 21 (SD 13) months (median 18; range 6–43 months).

DISCUSSION

Keratoacanthoma was first described by Hutchinson,¹¹ more than 115 years ago, as a "crateriform ulcer of the face", and since then it continues to be a source of debate as to the exact pathogenesis and preferred management.^{1–5}

The predilection of keratoacanthoma for sun exposed areas suggests ultraviolet (UV) radiation is an important aetiological factor. Other possible factors in the pathogenesis include immunosuppression, exposure to chemical agents, human papilloma virus infection, chronically injured skin (ulcers, burns, sinus tracts, vaccination scars, and chronic skin diseases), and genetic aberrations.^{3–5}

Abbreviations: PNI, perineural invasion; SCC, squamous cell carcinoma.

Table 1 Clinical characteristics and postoperative outcome of patients with histologically proven periocular keratoacanthoma

Patient	Age/sex	Site	Tumour duration (weeks)	Tumour diameter (mm)	Tumour excision	Defect size (mm)	No of excision levels	Reconstruction method	Follow up (months)	Recurrence
1	41/M	LL	6	5	MMS	7×8	1	Primary closure	12	No
2	76/F	LL	8	8	F/S	11×10	1	Tenzel flap	29	No
3	57/M	LL	20	20	F/S	24×22	1	Hughes flap	43	No
4	81/M	LC	7	16	F/S	10×8	1	FTSG	14	No
5	74/F	UL	12	9	MMS	15×16	2	Reverse Tenzel	21	No
6	68/M	LL	8	8	F/S	10×11	1	Tenzel flap	12	No
7	58/F	UL	16	19	MMS	18×19	2	Tarsoconjunctival transposition	35	No
8	77/M	MC	10	12	MMS	12×12	1	FTSG	30	No
9	72/F	MC	4	5	MMS	6×7	1	Bilobed flap	8	No
10	64/M	LL	5	17	MMS	25×20	3	Hughes flap	6	No

UL, upper lid; MC, medial canthus; LL, lower lid; MMS, Mohs micrographic surgery; F/S, frozen section control; FTSG, full thickness skin graft.

The annual incidence of cutaneous keratoacanthoma varies according to geographical location. It was estimated to be 104 cases per 100 000 in Hawaii,¹² and as high as 150 cases per 100 000 in the northern areas of Australia.¹³ It commonly affects patients in their fifth to seventh decades, and in most series appears to be much more common in males.^{1-3,5} In our series there was a slight male predominance (55.6%), and the mean age (67 (SD 13) years) was similar to other reports on cutaneous keratoacanthoma. The exact reason for the male predominance in these series is not clear.

Although there is an obvious predilection of the tumour for the face,¹⁻³ periocular involvement is uncommon and has been reported in only a small number of series in the ophthalmic literature. In one of the earliest series, Baer and Kopf reviewed 592 cases of keratoacanthoma, and found that more than 70% of tumours were located on the face, and 33 cases were periocular (5.6%).¹⁴ Boniuk and Zimmerman reported a large series of 44 patients with periocular keratoacanthoma; 58% were located on the lower lid, 35% on the upper lid, and 7% on the medial or lateral canthi.⁶ In a recent report, Donaldson *et al* reported another 10 patients with periocular keratoacanthoma; 50% of the lesions were located on the lower lid, 20% on the upper lid, 20% on the medial canthus, and 10% on the lateral canthus.¹⁰ Similar distribution was found in our series. This distribution correlates with the degree of sun exposure, and is also found in other UV induced periocular tumours, such as basal cell carcinoma and squamous cell carcinoma.

Solitary keratoacanthomas are characterised by three clinical stages: (1) a proliferative/growth phase which lasts 2–10 weeks, (2) a stationary period of similar duration, and (3) resolution/involution phase of up to one year duration.³ There are also several variants of keratoacanthoma which are of clinical importance: the giant keratoacanthoma (exceeding 3 cm in diameter), keratoacanthoma centrifugum marginatum (characterised by progressive peripheral growth and ventral healing), subungual keratoacanthoma (painful destructive keratoacanthoma of the nail), mucosal keratoacanthoma (affecting mucous membranes), and multiple keratoacanthomas (usually associated with the Ferguson

Smith type, the Grzybowski type, Muire-Torre syndrome, and xeroderma pigmentosum).^{1-3,5} During the proliferative phase, a firm hemispheric papule grows rapidly. The border of the papule is skin coloured or slightly erythematous, and fine telangiectatic vessels may be evident.⁴ When it reaches its mature form, it is bud shaped or dome shaped, with a central, umbilicated, keratinous core. All our patients presented with this characteristic tumour morphology (fig 1A and 1B) and a history of a rapidly growing lesion (mean duration from tumour appearance to clinical diagnosis was 10 (SD 5) weeks; range 4–20 weeks), and this was the basis for the initial clinical diagnosis of keratoacanthoma. The mean tumour size in our series was 12 (SD 6) mm (range 5–20 mm). Boniuk and Zimmerman reported that 82% of the tumours were present for less than two months, and most lesions were smaller than 8 mm.⁶ Donaldson *et al* found a slightly longer duration of symptoms before diagnosis (mean 5.4 months; median 3 months), but a similar tumour size (mean 7.2 mm; range 2–25 mm).¹⁰ Interestingly, while reviewing the literature, we found no cases of giant periocular keratoacanthomas (measuring more 30 mm), and the majority of reported tumours were smaller than 10 mm.

Shave or incisional punch biopsies are usually inadequate to diagnose keratoacanthoma, and the definite diagnosis can only be established after tumour excision, based on the cytological and architectural findings.⁴ Histologically, mature lesions demonstrate a central keratin-filled crater with a surrounding buttress of epidermis (fig 2A). They are composed of tumour islands made of enlarged keratinocytes with a pale cytoplasm, arranged in concentric layers with increasing keratinisation centrally (fig 2B). These cell nests extend to the dermis, to the level of the sweat glands. The large cells with pink cytoplasm towards the centre of the tumour cell nests are generally more characteristic of keratoacanthoma.¹⁻³ Inflammatory cells are usually found in the stroma, at the base of the lesion. The distinction between keratoacanthoma and SCC is not always simple. Various markers such as involucrin and lectins were not specific enough, and could not be used in clinical practice.^{3,5} In a

Table 2 Clinical characteristics and postoperative outcome of patients diagnosed with invasive squamous cell carcinoma

Patient	Age/sex	Site	Tumour duration (weeks)	Tumour diameter (mm)	Tumour excision	Defect size (mm)	No of excision levels	Histology	Reconstruction method	Follow up (months)	Recurrence
1	60/M	LL	8	6	MMS	14×16	3	Well diff SCC, + PNI	Hughes flap	17	No
2	70/M	LL	8	10	F/S	17×12	1	Mod/ well diff SCC, no PNI	Tenzel flap	5	No

LL, lower lid; MMS, Mohs micrographic surgery; SCC, squamous cell carcinoma; PNI, perineural invasion; F/S, frozen section control.

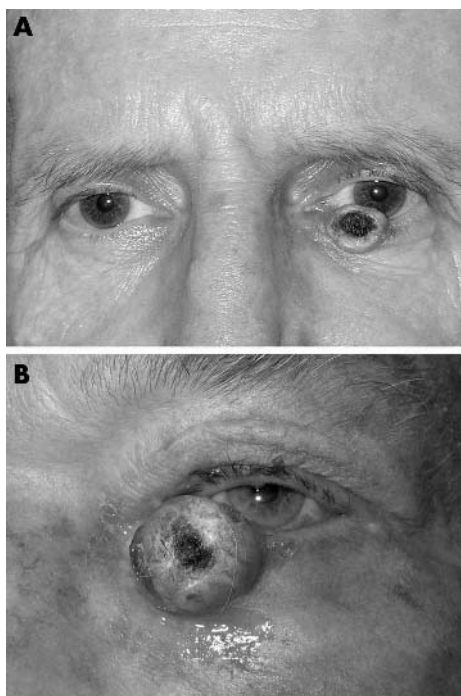


Figure 1 The mature phase of a left lower lid keratoacanthoma. (A) A large central keratinous core. (B) A narrow central core.

recent report by Cribier *et al* the authors studied 296 fully excised tumours, previously classified as keratoacanthoma or SCC, and analysed the histopathological criteria differentiating the two tumours.¹⁵ They concluded that the most important criteria were an epithelial lip and a sharp outline demarcation between the tumour and the stroma (favouring keratoacanthoma), and ulceration, pleomorphism/anaplasia, and numerous mitoses (favouring SCC). Perineural invasion (PNI) is an uncommon finding in keratoacanthoma, and when present, it does not affect prognosis or the risk of metastatic disease.²⁻¹⁶ No cases of PNI were recorded in any of our keratoacanthoma patients. One of our other two patients, with a final diagnosis of SCC, was also diagnosed with intratumoural PNI.

It is well recognised that keratoacanthomas can regress spontaneously, without any treatment.¹⁷ During the involutory phase the lesion becomes flattened and less crateriform, and granulation tissue appears at the base, resulting in a scar at the area of the tumour. Most authors advocate complete excision of the tumour as opposed to conservative management. Tumour excision provides tissue for accurate histological diagnosis, hastens cure, prevents rapid growth, and maintains normal function of involved organs. Another factor which favours complete removal of keratoacanthomas is the significant overlap in the clinical and histological appearance of keratoacanthoma and invasive SCC, which may possibly lead to misdiagnosis of SCC as keratoacanthoma. In addition, the initial lesion may be a combined keratoacanthoma and SCC, or there could have been a transformation to SCC at some point in the evolution.²

Early excision of periocular keratoacanthoma is essential, not only to maintain normal eyelid function, but also to prevent further tissue destruction and invasion into deeper tissues. This is supported by Grossniklaus *et al* who presented three cases of invasive keratoacanthoma; one involved skeletal muscle and two had PNI (one of them extending into the cavernous sinus).⁹ The importance of complete excision of keratoacanthoma is further emphasised by our

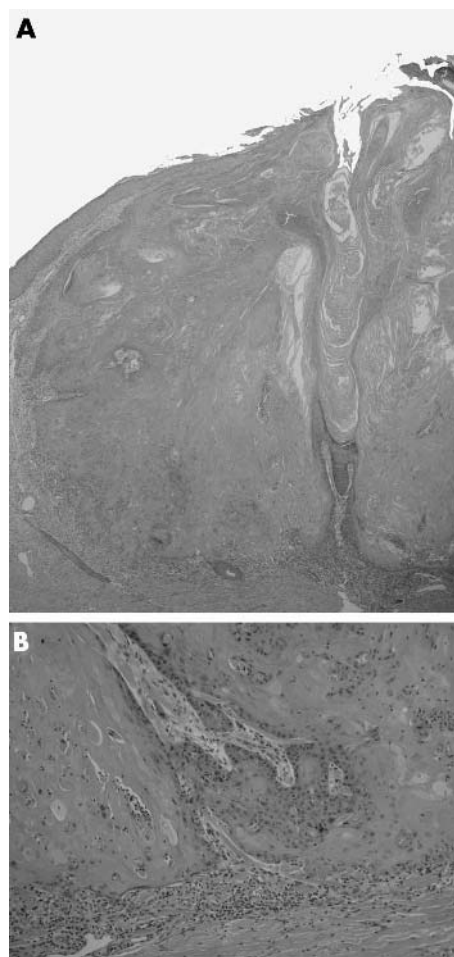


Figure 2 Keratoacanthoma. (A) A central keratin-filled crater with a surrounding buttress of epidermis (haematoxylin and eosin $\times 20$ magnifications). (B) Islands of enlarged keratinocytes with a pale cytoplasm, arranged in concentric layers with increasing keratinisation centrally. Dermal infiltrate of lymphocytes and histiocytes (haematoxylin and eosin $\times 40$ magnifications).

findings that 16.7% of the lesions in our study, initially diagnosed as keratoacanthoma based on the clinical presentation (fig 3A) and initial biopsy, eventually proved to be invasive SCC (fig 3B and 3C). When left untreated, these aggressive tumours can be locally destructive, invade the orbit,¹⁸ metastasise,¹⁹ and even result in death.²⁰ Therefore, the role of alternate treatments such as curettage and electrodissection, cryotherapy, radiotherapy, or intralesional chemotherapy, is probably limited to patients unable to tolerate surgery. Hence, it is generally accepted that surgical excision with margin control is the most appropriate method for solitary tumours, with recurrence rates of 4–8% for cutaneous keratoacanthomas.^{4,5} Boniuk and Zimmerman treated most of their 44 periocular keratoacanthomas with surgical excision (margin control was not specified), and had no cases of recurrence during a follow up period ranging from 8 months to 11 years.⁶ Donaldson *et al* treated all their patients with surgical excision (five of them were margin controlled with frozen section), and on pathological examination, all lesions were shown to be completely excised, with clear margins.¹⁰ They noted no cases of recurrence during a mean follow up period of 34.5 months. Six patients (60%) in our series underwent Mohs surgery, and four (40%) underwent tumour excision with frozen section control. There were no cases of recurrence during a mean follow up of

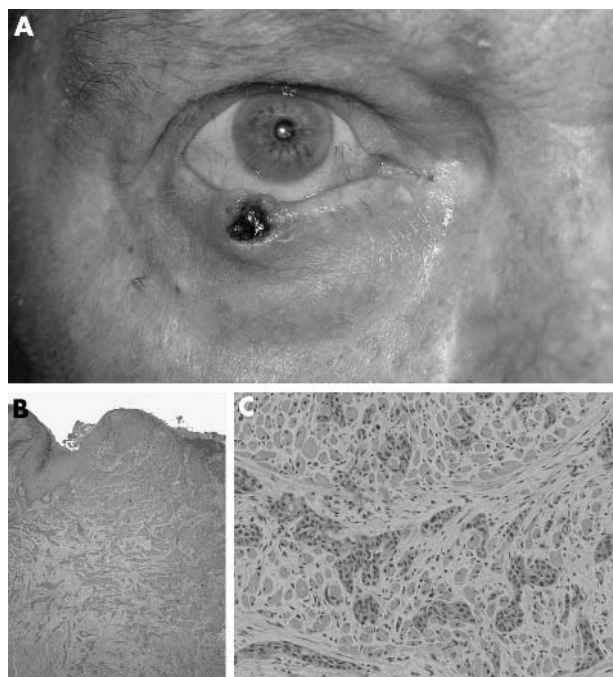


Figure 3 (A) Right lower lid rapidly growing crater shaped tumour diagnosed clinically as keratoacanthoma. (B) Nests of squamous epithelial cells arising from the epidermis and extend into the dermis, consistent with an invasive SCC (haematoxylin and eosin $\times 20$ magnifications). (C) Cells show abundant eosinophilic cytoplasm and large vesicular nuclei (haematoxylin and eosin $\times 200$ magnifications).

21 months (range 8–40 months). There are only a few studies on the role of Mohs surgery in the treatment of keratoacanthoma, and none of these studies referred specifically to periocular tumours. Mohs treated 115 patients with keratoacanthoma, and recorded no cases of recurrence. Larson reported 43 patients with keratoacanthomas treated with Mohs surgery, most of them were located on the face. The recurrence rate in his series was 2.4%.²²

In conclusion, periocular keratoacanthoma is a rare tumour that can be locally destructive and invasive. Although the clinical and morphological presentation is characteristic in most cases, it cannot always be differentiated from invasive SCC, and a definite diagnosis requires complete tumour excision. Our series suggests that a significant proportion of tumours that clinically are thought to be keratoacanthoma will prove to be invasive SCC. Hence, we believe there is no role for observation, curettage, or alternate destructive treatment modalities in the majority of patients. Surgical excision with margin control using frozen sections or Mohs surgery should be considered for lesions in

the periocular area as it offers definitive diagnosis, tissue conservation, and a low recurrence rate.

Authors' affiliations

I Leibovitch, G Davis, D Selva, Oculoplastic & Orbital Unit, Department of Ophthalmology and visual sciences, Royal Adelaide Hospital, University of Adelaide, South Australia

S C Huilgol, Department of Dermatology, Royal Adelaide Hospital, University of Adelaide, South Australia

C L James, Adelaide Pathology Partners, Adelaide, South Australia

J D Hsuan, Department of Ophthalmology, Walton Hospital, Liverpool, UK

REFERENCES

- 1 Weedon D. Tumors of the epidermis. In: Weedon D, eds. *Skin pathology*. London: Churchill Livingstone, 1997:657–60.
- 2 Godbolt AM, Sullivan JJ, Weedon D. Keratoacanthoma with perineural invasion: a report of 40 cases. *Aust J Dermatol* 2001;**42**:168–71.
- 3 Weedon D. Keratoacanthoma: a personal perspective. *Curr Diag Path* 2003;**9**:259–65.
- 4 Schwartz RA. Keratoacanthoma. *J Am Acad Dermatol* 1994;**30**:1–19.
- 5 Schwartz RA. Keratoacanthoma: a clinico-pathologic enigma. *Dermatol Surg* 2004;**30**:326–33.
- 6 Boniuk M, Zimmerman LE. Eyelid tumors with reference to lesions confused with squamous cell carcinoma. III. Keratoacanthoma. *Arch Ophthalmol* 1967;**77**:29–40.
- 7 Lalla M, Thomas BA. Periorbital keratoacanthoma. *Br J Ophthalmol* 1968;**52**:876–81.
- 8 Requena L, Romero E, Sanchez M, et al. Aggressive keratoacanthoma of the eyelid: "malignant" keratoacanthoma or squamous cell carcinoma? *J Dermatol Surg Oncol* 1990;**16**:564–8.
- 9 Grossniklaus HE, Wajno TH, Yanoff M, et al. Invasive keratoacanthoma of the eyelid and ocular adnexa. *Ophthalmology* 1996;**103**:937–41.
- 10 Donaldson MJ, Sullivan TJ, Whitehead KJ, et al. Periocular keratoacanthoma: clinical features, pathology, and management. *Ophthalmology* 2003;**110**:1403–7.
- 11 Hutchinson J. The crateriform ulcer of the face: a form of epithelial cancer. *Trans Pathol Soc London* 1889;**40**:275–81.
- 12 Chuang TY, Reizner GT, Elpern DJ, et al. Keratoacanthoma in Kauai, Hawaii. The first documented incidence in a defined population. *Arch Dermatol* 1993;**129**:317–19.
- 13 Sullivan JJ. Keratoacanthoma: the Australian experience. *Australas J Dermatol* 1997;**38**(Suppl 1):S36–39.
- 14 Baer RL, Kopf AW. Keratoacanthoma. In: Baer RL, Kopf AW, eds. *Year book of dermatology*. Chicago: Year book medical publishers, 1962–63, 7–41.
- 15 Cribier B, Asch P, Grosshans E. Differentiating squamous cell carcinoma from keratoacanthoma using histopathological criteria. Is it possible? A study of 296 cases. *Dermatology* 1999;**199**:208–12.
- 16 Feasel AM, Brown TJ, Bogle MA, et al. Perineural invasion of cutaneous malignancies. *Dermatol Surg* 2001;**27**:531–42.
- 17 Griffiths RW. Keratoacanthoma observed. *Br J Plast Surg* 2004;**57**:485–501.
- 18 McNab AA, Francis IC, Bengier R, et al. Perineural spread of cutaneous squamous cell carcinoma via the orbit. Clinical manifestations and outcome in 21 cases. *Ophthalmology* 1997;**104**:1457–62.
- 19 Faustina M, Diba R, Ahmadi MA, et al. Patterns of regional and distant metastasis in patients with eyelid and periocular squamous cell carcinoma. *Ophthalmology* 2004;**111**:1930–2.
- 20 Reifler DM, Hornblase A. Squamous cell carcinoma of the eyelid. *Surv Ophthalmol* 1986;**30**:349–65.
- 21 Mohs FE. Keratoacanthoma. In: Mohs FE, eds. *Chemotherapy: microscopically controlled surgery for skin cancer*. Springfield, IL: Charles C Thomas, 1978:286–7.
- 22 Larson PO. Keratoacanthomas treated with Mohs's micrographic surgery (chemosurgery). A review of forty-three cases. *J Am Acad Dermatol* 1987;**16**:1040–4.